

Management of a case of laryngotracheal esophageal cleft type III with review of literature

U. Badole, S. D. Mundada, S. Patil, A. Rathod

Department of Anaesthesia and Critical Care, Sir J. J. Group of Hospitals, Mumbai India

Corresponding author: S. D. Mundada, Department of Anaesthesia and Critical Care, Sir J. J. Group of Hospitals, Mumbai, India. Email: suranesthesia@gmail.com

Key points

Laryngotracheal esophageal cleft (LTEC) is a rare developmental disorder of upper airway which accounts for 0.3% to 0.5% of all congenital anomalies of the larynx. It demands high clinical judgment to diagnose the case as most of the times patient is erroneously diagnosed as tracheoesophageal fistula and recurrent esophageal intubation or slipping of endotracheal tube in the esophagus should arise suspicion of LTEC. It has been divided into four types by Benjamin and Inglis and severity depends upon type. Type III and IV present with severe symptoms in the neonatal period. Knowledge of different approaches to secure and maintain airway and preparedness for the same in such a case is most important to prevent catastrophic events.

Abstract

Laryngotracheal esophageal cleft (LTEC) is an abnormal communication of larynx and trachea with esophagus via a midline defect. This anomaly occurs in less than 1% of population, and has slight male preponderance. Diagnosis of such a case requires great degree of suspicion as it is commonly mistaken for tracheoesophageal fistula. Though cases have been described in otolaryngology literature, there are very few cases available that describe the anesthesia challenges and management of LTEC. Here we describe the anesthesia management of a neonate with Type III LTEC along with review of literature of the same.

Keywords: Airway management, laryngotracheal esophageal cleft, pediatric difficult airway

Introduction

Laryngotracheal esophageal cleft (LTEC) is a rare developmental disorder of upper airway which accounts for 0.3% to 0.5% of all congenital anomalies of the larynx.^{[1][2]}

The trachea and esophagus originate from one common tube and are separated by the rostral development of the tracheoesophageal septum, which is complete at approximately 35 days of gestation. Complete or partial failure of the septum to develop results in a laryngotracheoesophageal (LTE) cleft. A simple and clinically applicable is that proposed by Benjamin and Inglis that divides the clefts into four types based on function. Most of the times the diagnosis is presumed to be trachea esophageal fistula hence It demands high clinical judgment to diagnose the case as well as greater skills to manage airway perioperatively in patients with congenital laryngeal cleft. We present a neonate who was diagnosed as LTEC type III and describe the anesthetic challenges faced during its surgical correction along with review of literature of the anaesthesia techniques that have been used in past.

Case report

A 3 day old neonate, male, weighing 3kg was referred to our institution from private hospital with the recurrent

episodes of choking and cyanosis after feeding, and respiratory distress. The baby was born at 32-weeks gestation to a 25-year-old gravida 1 para 1 female. The pregnancy was complicated by polyhydramnios. Labor commenced after spontaneous rupture of membranes, and the infant was delivered vaginally with Apgar scores of 7 at 1 min and 9 at 5 min. The typical history made the pediatric surgeons suspect a trachea-oesophageal communication so he was posted for diagnostic rigid bronchoscopy. His already bad lung dissuaded them from carrying on a esophgogram with a dye as further dye aspiration could be catastrophic for the baby. An Ultrasound (usg) abdomen, 2 D echo and ophthalmic reference for defects were advised. Usg abdomen was normal and 2 D echo showed a small patent ductus arteriosus and a small atrial septal defect. There were no ophthalmic defects.

His chest x ray showed haziness in the right middle and upper lobe suggestive of aspiration pneumonitis. His haemoglobin was 13gm% and wbc count 15000.

On examination baby was floppy with weak cry but was maintaining saturation of 90% on hood and prone position. So he was not intubated in the pediatric intensive care unit (PICU). He also had low set ears and dysmorphic facies.

He was taken up for diagnostic bronchoscopy with repair under general anaesthesia. In ot, monitoring included pulse oximetry, capnography, electrocardiogram, temperature, noninvasive blood pressure and urine output.

Patient was given fentanyl 6mcg and atropine 0.06 mg intravenous (IV). Anesthesia was induced by inhalation of oxygen and sevoflurane. Muscle relaxation was achieved with atracurium 1mg IV. Rigid bronchoscopy with a 2.5 mm sized scope showed a large Laryngotracheal- oesophageal cleft (LTEC) extending up to middle of trachea (Type III LTEC) (Fig. 1) The bronchi were normal.

Decision was taken to repair the cleft as he was prone to aspiration. We then tried to intubate the patient with 3

mm ETT under direct laryngoscopy (DL) after achieving a grade I view. Tube placement was confirmed with ET CO_2 and bilateral breath sounds. On surgeons insistence we took the tube from right side of mouth to left (as they wanted the head turned to the left) but now we were unable to ventilate the patient. We reintubated the patient by passing the tube through the previously entered opening but were unable to ventilate the patient.

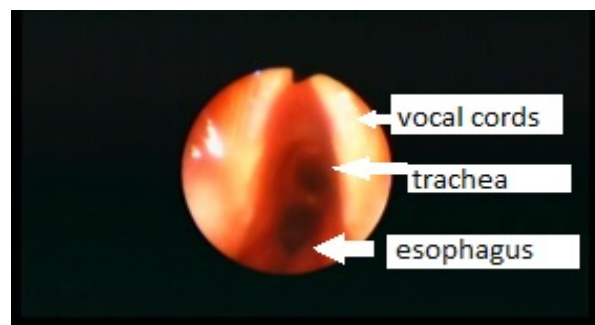


Fig. 1. Laryngotracheal-oesophageal cleft

This happened twice so we decided to place two tubes one in what we thought was larynx and other in the oesophagus and this time we were able to ventilate through the tube we thought was in oesophagus. After confirming bilateral breath sounds and ET CO_2 tracings we removed the other ET tube and placed a large bore (10F) nasogastric tube.

Head was carefully turned to right and incision was taken on the left side of neck.

There was a posterior laryngeal cleft extending from just below the vocal cords till the suprasternal notch with a common tracheo-oesophageal passage. The cleft was repaired by placing long strips of sternomastoid muscle between trachea and esophagus. The trachea was repaired over the 3 mm ETT. Esophagus was repaired over the nasogastric tube (Fig. 2). We did not encounter any tube displacement during surgery but there lot of air leak while ventilating the patient which was overcome by turning the bevel of the tube anteriorly. Anesthesia was maintained using atracurium and sevoflurane. Inj fentanyl boluses were given for analgesia.

The surgery was completed uneventfully over 3 hours. The oxygen saturation and hemodynamic parameters

were stable during this period. Blood loss was minimal and 40 ml of Ringer Lactate was given as infusion during surgery.

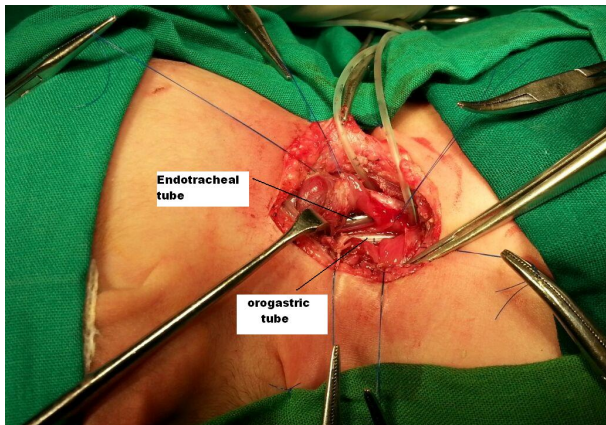


Fig. 2. Esophagus repaired over the nasogastric tube

Patient was shifted to PICU and electively ventilated for 3 days. Infusion of fentanyl 1mcg/kg/hr was given for 48 hrs. On the 3rd day attempts to wean the patient were made but he did not maintain blood pressure and become vitally unstable. Though dopamine infusion and higher antibiotics were started he subsequently developed septicaemia and renal failure and died on 5th postoperative day.

Discussion

Disruption in the cephalad development of the laryngo-tracheal septum results in a laryngeal cleft defect^[1]. It has been proposed also by Merei and Hutson^{[1][8]} that an LTE cleft may occur as a result of failure of the laryngo-tracheal diverticulum to form from the foregut. There are no definitive contributing factors associated with these defects, although adriamycin has been reported to induce esophageal atresia and tracheoesophageal fistula in fetal rats^[2]. A nonspecific finding of polyhydramnios and prematurity has been associated with LTEC^[3].

In our case patient had history of polyhydramnios with child being born prematurely. LTEC defects may be associated with other congenital anomalies and have been described in two syndromes: Opitz–Frias (or G syndrome) and Pallister–Hall syndrome^[3]. Opitz–Frias syn-

drome includes hypertelorism, cleft lip/palate, cleft larynx, and hypospadias. Pallister–Hall syndrome is associated with hypothalamic hamartoblastoma, hypopituitarism, imperforate anus, postaxial polydactyly, and cleft larynx. Laryngeal clefts have also been found in patients with VATER association, and patients with laryngeal cleft defects may have a coexisting tracheoesophageal fistula (almost 20%), meckel’s diverticulum, GERD, congenital subglottic stenosis as well^[6].

The Benjamin Inglis classification of LTEC is the simplest and most commonly used. Type I involves inter-arytenoid musculature, Type II involves the cricoid only, Type III involves the proximal larynx, trachea and oesophagus and Type IV LTEC extend into the thoracic trachea and may extend down to the carina^[4,5]. These classifications are extremely important not only for surgical management but for anesthetic management as well. Symptoms associated with LTEC depend on the severity of the cleft and includes hoarse or husky voice, feeding difficulties, increased secretions, choking, stridor, aspiration, pneumonia, and cyanotic episodes. Major clefts (types III and IV) may be associated with stridor and/or respiratory distress. Types III and IV LTEC often require airway intervention soon after birth along with difficulties in maintaining an intubated airway^[3].

Differential diagnosis of LTEC include tracheoesophageal fistula, esophageal stricture, neuromuscular disease, laryngomalacia as each of the forementioned also have similar presenting symptoms. Hence diagnosis of LTEC requires high degree of suspicion. An accurate diagnosis of LTEC requires the following findings/or investigations- CXRay suggestive of aspiration pneumonia, ability to pass nasogastric tube that shows an anterior posterior position on xray, laryngoscopy and bronchoscopy, oesophagogram, oesophagoscopy and a CT scan.

Most of the cases reported in literature the diagnosis were made incidently when the patient were brought in for tracheo oesophageal fistula repair. The latest was described in Indian Journal where patient was taken up for trachea oesophageal repair. The inadequacy to main-

tain ventilation even though a large size tube was introduced raised suspicion and bronchoscopy was performed to find a complicated type IV LTEC. Repeated oesophageal intubations, recurrent slipping of tube into the oesophagus inspite of tracheal intubation are all signs that warrent further investigation^[7].

Surgical correction depends on variety of features including severity of symptoms, associated anomalies and syndromes, and type of cleft. Type I usually gets corrected with growth and does not require any surgical management. Type II can be managed endoscopically with microlaryngoscopy, CO₂ laser stripping of the mucosal layer of cleft and sutures to close the cleft. Type III and IV require an open approach to access the posterior cleft. The exposure of LTEC consists of a cervical approach that includes a thyrotomy, cricoidotomy, and tracheofissure opening. type IV LTEC may require an additional lateral thoracotomy and cases using cardiopulmonary bypass and midline sternotomy have also been described.

Anaesthesia management of type III and IV remains a challenge. Preoperatively most patients will have some form of GERD which will have to be controlled medically or through gastrostomy and fundoplication.

Intraoperatively the difficulty to intubate depends on the type of cleft. Type III requires stylet/ mainstem intubation with carefully withdrawing the endotracheal tube (ETT) till adequate ventilation is achieved. Incase of repeated oesophageal intubation and inability to ventilate, insertion of two tubes one in both the openings is advisable and ventilation can then be checked through them as done in our case. Orientation of bevel of tube anteriorly helps to minimize air leak into esophagus posteriorly. In type IV a cuffed ETT or fogatory catheter into the oesophageal orifice and an ETT into the anterior portion of trachea has been mentioned. In case described by Arai LR et al, deliberate oesophageal intubation using a large size tube to ventilate a neonate with type IV LTEC has been described. Later the patient was taken on cardiopulmonary bypass for sternotomy^[8].

Ruder managed the airway of typeIII LTEC with a tracheal tube and a Foleys catheter passed into the stomach and the inflated balloon retracted into the gastro-oesophageal junction^[9]. The Foleys catheter provided a seal in preventing gas from entering the stomach during positive pressure ventilation, besides helping to maintain an anterior position of the ETT and preventing it from being displaced posteriorly into the esophagus. We found that a large bore nasogastric tube (10 F) passed into the esophagus was useful in decompressing the stomach and prevented ETT displacement.

Yoshizawa described the use of one-lung ventilation with left endobronchial intubation for surgical repair of LTE cleft via a right thoracotomy^[10]. Other strategies include prior tracheostomy, two tracheal tubes into each main stem bronchus,^[3] custom-made bifurcated ETT,^{[1],[5]} pediatric bilumen tube^[11], laryngeal mask airway^[12]. Using ECMO and avoiding intubation or tracheostomy has also been described by Geiduschek^[13].

Maintaining the airway and prevention of aspiration during reconstruction is also difficult. An ETT anchored at the angle of mouth, a large bore nasogastric tube and close vigilance to detect and rectify any tube displacement helped us to tide over the intraoperative period.

Postoperatively, the patients require prolonged ventilatory support because of the posterior tracheal wall defect and tracheobronchomalacia. Nutritional status has to be maintained for the wound healing and neonatal growth. Gastric transection with double gastrostomies, gastrostomy, and total parenteral nutrition has been reported^[1]. Gastro-oesophageal reflux leads to aspiration pneumonia, sepsis and increased mortality. Proton pump inhibitors, histamine type 2 antagonists, proximal gastric drainage, Nissen fundoplication, high gastric transection, double gastrostomy have been advocated. Other complications of surgery include tracheo-oesophageal fistula, laryngeal nerve injury, granulation tissue formation, tracheomalacia and dysmotility of reconstructed esophagus^[2]. The mortality rate for an LTE cleft increases with severity, ranging from approximately 43% in

Types II and III to 90% for Type IV^[14]. Patients with these defects require early diagnosis and intervention to prevent significant pulmonary damage from aspiration. A multidisciplinary team approach and effective communication between team members are essential in the management of these patients.

Conclusion

In summary, we describe the successful anesthesia management of a neonate with Type III LTEC and discuss the pertinent issues for management of a patient with this type of defect. High clinical suspicion, preparedness for difficult airway and knowledge about different approaches to manage these cases are necessary as often immediate correction may be required.

Acknowledgements

This case is written after written assent of the parents of the baby.

References

1. Chitkara AE, Tadros M, Kim HJ, Harley EH. Complete laryngotracheoesophageal cleft: Complicated management issues. *Laryngoscope* 2003;113:1314-20.
2. Pezzettigotta SM, Leboulanger N, Roger G, Denoyelle F, Garabedian EN. Laryngeal cleft. *Otolaryngol Clin North Am* 2008;41:913-33.
3. Carlson BM. *Human Embryology and Developmental Biology*. St. Louis: Mosby-Year Book, 1994: 325-326.
4. Merei JM, Hutson JM. Embryogenesis of tracheoesophageal anomalies: a review. *Pediatr Surg Int* 2002; 18: 319-326.
5. Chitkara AE, Tadros M, Kim HJ et al. Complete laryngotracheoesophageal cleft: complicated management issues. *Laryngoscope* 2003; 113: 1314-1320.
6. Roth B, Rose KG, Benz-Bohm G, Gunther H. Laryngo-tracheal- esophageal cleft: clinical features, diagnosis, and therapy. *European Journal of Pediatrics* 1983;140:41-46.
7. Dwarakanath S, Reddy A. Unexpected presentation of a type IV laryngo-tracheo-oesophageal cleft: Anaesthetic implications of a rare case. *Indian J Anaesth* 2014;58:746-8.
8. Arai LR, Dicindio S, Cook SP, Davis DA. Anesthesia management of a patient with a laryngotracheo-esophageal cleft. *Paediatr Anaesth* 2007;17:171-5.
9. Ruder CB, Glaser LC. Anaesthetic management of laryngotracheoesophageal cleft. *Anesthesiology* 1997;47:65-7.
10. Horimoto Y, Yoshizawa M. Intraoperative one-lung ventilation for total laryngotracheoesophageal cleft. *Middle East J Anesthesiol* 1990; 10: 519-525.
11. Marraro G. Selective endobronchial intubation in paediatrics: The Marraro paediatric bilumen tube issue. *Paediatr Anaesth* 1994;4:255-8.
12. Johr M, Berger TM, Ruppen W, Schlegel C. Congenital laryngotracheoesophageal cleft: Successful ventilation with the laryngeal mask airway. *Paediatr Anaesth* 2003;13:68-71.
13. Geiduschek JM, Inglis AF Jr, O'Rourke PP, Kozak FK, Mayock DE, Sawin RS. Repair of a laryngotracheoesophageal cleft in an infant by means of extracorporeal membrane oxygenation. *Ann Otol Rhinol Laryngol* 1993;102:827-33.
14. Moukheiber AK, Camboulives J, Guys JM et al. Repair of a type IV laryngotracheoesophageal cleft with cardiopulmonary bypass. *Ann Otol Rhinol Laryngol* 2002; 111: 1076-1080.